


The Distal Seal Zone in AAA Repair

A facet of EVAR that is not to be overlooked.

BY THEODOSIOS BILDAS, MD, AND GIOVANNI TORSSELLO, MD



Compared to the open surgical approach, endovascular aneurysm repair (EVAR) has demonstrated a clear benefit of lower perioperative mortality and morbidity, as well as comparable long-term survival rates in randomized controlled trials.¹ However, the higher reintervention rates remain the Achilles' heel of EVAR (relative risk, 2.54; 95% confidence interval, 1.58–4.08).¹ Hence, the ongoing refinement of the new generation of endografts is now targeting the reduction of device-related reinterventions.²

Most of the attention regarding secondary procedures has been focused on different anatomic challenges at the proximal sealing zone (angulated or short necks, calcifications or thrombus) and into the aneurysm sac (type II endoleak).³ However, the distal seal zone (DSZ) also presents a distinct set of challenges but has received less attention in the literature. In this article, we discuss the complexity of the DSZ and present different endovascular solutions to overcome anatomic and technical challenges.

HOSTILE DSZ

There is no clear definition of a hostile DSZ in the literature. In this article, we use the term “hostile DSZ” to describe anatomic challenges at the distal aortic neck and in the common iliac arteries. In contrast to the proximal neck, the DSZ can complicate endograft sealing not only through progression of the aneurysmatic disease but also through the presence of stenotic or tortuous iliac vessels. The following scenarios could lead to poor outcomes after endograft implantation: (1) aneurysmatic degeneration (at the primary procedure or further progression of the disease) at the level of the common or internal iliac arteries, (2) narrow distal neck or stenotic iliac arteries, and (3) tortuous iliac vessels.

ANEURYSMATIC DSZ OR FURTHER DISEASE PROGRESSION POST-EVAR

Epidemiological studies have shown that in 25% of patients older than 65 years who have an abdominal

aortic aneurysm (AAA), the disease extends into one or both common iliac arteries, and in 7% of these patients, the disease extends into the internal iliac arteries.⁴ External iliac artery aneurysms are extremely rare. It is speculated that the external iliac artery is resistant to aneurysm formation because it arises from the extra-embryonic anlage, in contrast to the common and internal iliac arteries, which arise from the somites.⁴ A key procedural issue with aneurysmatic iliac arteries is to achieve a compact DSZ to avoid a type IB endoleak or distal endograft migration in the long run.

Several endovascular approaches have been suggested to achieve a safe landing zone in aortoiliac aneurysms or to repair further aneurysmatic degeneration due to progression of the disease. The first approach is to extend the iliac limb into the external iliac artery by embolizing or overstenting the internal iliac artery.⁵ However, occlusion of the internal iliac artery may cause buttock claudication, impotence, and bowel necrosis in up to 55% of patients.⁵ An alternative strategy is the “bell-bottom” technique, which has shown encouraging midterm outcomes (2.3% type IB endoleaks in 89 patients with common iliac artery aneurysms < 30 mm).⁶ However, common iliac artery aneurysms > 25 mm often cannot be effectively treated with this technique. Lobato et al established the “sandwich” technique to treat complex aortoiliac or isolated iliac aneurysms in 40 patients; the group showed 100% technical success and a primary patency rate of 94% after a mean follow-up period of 12 months.⁷ Yet, long-term evaluation of the technique is needed.

Use of an Iliac Side Branch Device for the DSZ

In this context, use of an iliac side branch device (Zenith Branch Iliac Graft*, Cook Medical, Bloomington, IN) provides a safe and effective approach to treat common or internal iliac artery aneurysms either at the primary procedure or due to the progression of the disease post-EVAR (Figure 1). Our early experience with endovascular repair of common iliac artery aneurysms < 26 mm in diameter with the straight iliac side branch device showed very low major morbidity (4.6%) and excellent

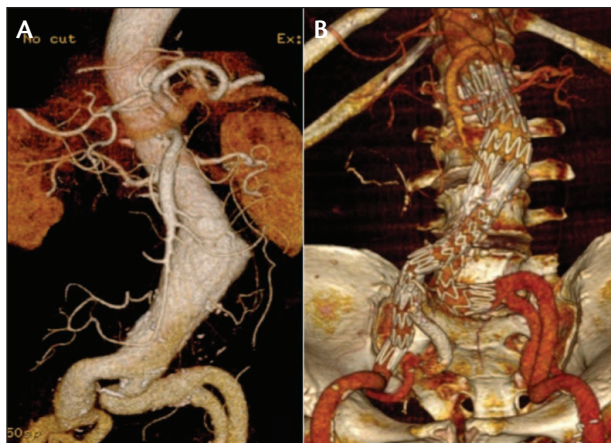


Figure 1. An aorto-mono-iliac aneurysm with a challenging DSZ consisting of an aneurysmatic and tortuous right common iliac artery (A). CT angiography (CTA) 3 years post-EVAR showing the successful exclusion of the aneurysm with a bifurcated endograft (Zenith) supported with an iliac side branch device for the right common iliac artery (B).

patency rates (98.4%).⁸ Meanwhile, during a period of 8 years (up to November 2013), we treated a total of 176 patients with 211 iliac side branch devices. The types of repaired aneurysms consisted of 60 aorto-bi-iliac aortic aneurysms (34%), 58 aorto-mono-iliac aortic aneurysms (33%), 54 common iliac artery aneurysms (31%, 10 bilateral), and four isolated hypogastric artery aneurysms (2%). Of note, three patients were treated due to progression of the aneurysmatic disease in the iliac arteries after previous EVAR (Figure 2). The reintervention-free survival rates were 83%, 77%, and 71% at 4, 6, and 8 years, respectively. Only six patients (3.4%) showed type I or III endoleaks, and the internal iliac side branch patency amounted to 81% at 5 years. Similarly, Wong et al reported the excellent performance of an iliac side branch device in different branch configurations (helical, bifurcated-bifurcated).⁹

Our Treatment Algorithm for Aneurysmatic Degeneration of DSZ

We have already reported our institution's algorithm for AAA repair with either primary involvement of the common iliac artery or as a result of further progression of the disease.^{6,8}

We recommend embolizing and overstenting the internal iliac artery only in cases where neither the bell-bottom technique nor the iliac side branch device are applicable. We always intend to overstent only one internal iliac artery. For common iliac artery aneurysms ≤ 25 mm in diameter, we advocate the bell-bottom technique as the treatment of choice.

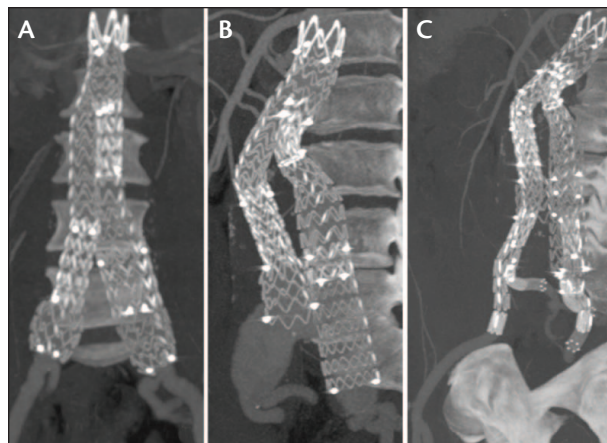


Figure 2. Postoperative CTA showing successful endovascular aneurysm exclusion using the bell-bottom technique for the right common iliac artery (A). Control CTA at 3 years revealing migration of the flexible right limb of the endograft with a type IB endoleak due to progression of aneurysmatic disease at the DSZ (B). Endovascular repair of the distal seal zone with bilateral implantation of iliac branch devices (C).

Our criteria for the use of iliac side branch devices consist of: (1) diameter of the common iliac artery > 28 mm, (2) length of the common iliac artery > 50 mm, and (3) adequate length of the external iliac artery > 15 mm. Common iliac artery aneurysms with a diameter between 26 and 28 mm still remain a gray zone in terms of the optimal endovascular approach. Our main treatment criteria for CIA aneurysms of this size are the clinical status of the patient and the diameter at the origin of the CIA. The bell-bottom technique is preferred in patients with limited life expectancy and narrow common iliac arteries, as the risk of a distal type I endoleak in such cases is low. Otherwise, the iliac side branch device remains the treatment of choice.

Aneurysmatic degeneration of the internal iliac artery is not an exclusion criterion for an iliac side branch device. We recently published our experience with the novel technique of using the iliac side branch device in combination with the Advanta V12 (Maquet Vascular Systems, Hudson, NH) and Viabahn (Gore & Associates, Flagstaff, AZ) stent grafts supported by a self-expanding stent to adequately seal the posterior trunk and exclude the internal iliac artery aneurysm (Figure 3).¹⁰

Finally, we recommend the use of balloon-expandable stent grafts (Advanta V12 or BeGraft [Bentley InnoMed GmbH, Hechingen, Germany]) as bridging endografts for the internal iliac artery. However, there has been an open debate about whether a balloon- or a self-expandable covered stent should be used as a bridging endograft for the iliac side branch devices. To inform the debate, we recently performed a pooled analysis of published single-

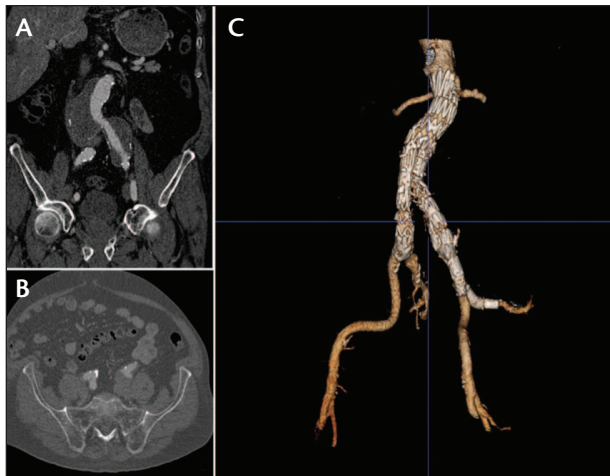

Figure 3. Use of an iliac side branch device to treat an aortoiliac aneurysm with a concomitant aneurysm of the left internal iliac artery (IIA). Preoperative CTA showing the aortoiliac aneurysm with involvement of the proximal IIA (A, B). Control CTA confirming successful treatment of the IIA aneurysm by combining a balloon-expandable and a self-expanding stent graft and relining them with a self-expanding nitinol stent up to the posterior trunk (C).

center experiences, which revealed better patency rates for the balloon-expandable bridging endografts.¹¹

NARROW DISTAL NECKS OR STENOTIC ILIAC ARTERIES

A narrow distal aortic neck is defined by the European Society of Vascular Surgery as one that is ≤ 20 mm in diameter.¹² Stenotic iliac arteries are considered to be < 7 mm in diameter.³ One technical concern during EVAR in patients with narrow distal aortic necks or stenotic iliac arteries is the risk of limb occlusion. Specifically, in a narrow distal neck, compression of the limb by means of a competition mechanism between the two limbs could be responsible for limb occlusion.¹³

Stent graft kinking has been independently related to the occurrence of graft limb occlusion (odds ratio, 12; 95% confidence interval, 3.4–42.1; $P = .0001$), and approximately 25% to 40% of the described occlusions in recent EVAR series have been correlated to this mechanism.¹³ The reported occlusion rates of currently used endografts are controversial between the studies and vary between 0% and 14%.^{14–17} Recently, Cieri et al reported the occurrence of 40 occlusions (3%) among 1,450 patients with different endovascular devices for AAA repair (AneuRx [Medtronic, Inc., Santa Rosa, CA], Talent [Medtronic, Inc.], Endurant [Medtronic, Inc.], Zenith [Cook Medical], Excluder [Gore & Associates], Fortron [Cordis Corporation, Bridgewater, NJ], and Anaconda

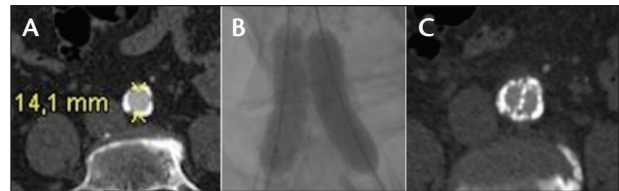


Figure 4. Stenting of both endograft limbs with the kissing-balloon technique in a napkin-ring aorta with a distal diameter of 14 mm. The preoperative diameter of the narrow distal aorta on CTA (A). Stent implantation with the kissing-balloon technique and paving-and-cracking method (B). CTA at 2 years showing the performance of both limbs in the narrow segment of the distal aorta (C).

[Vascutek Ltd., Inchinnan, UK]) over a mean follow-up of 45 months.¹⁷ In regard to the time of occlusion, van Zeggeren et al reported that 90% of the 20 limb occlusions were diagnosed within 1 year among 496 patients who were treated with the Endurant stent graft.¹⁸

Our Treatment Algorithm for Narrow Distal Aortas

Generally, the diameter of the distal aorta through which the two limbs must pass should be greater than the sum of their diameters.¹³ Failing this, there may be compression of one of the limbs or kinking. At present, there are no bifurcated endografts of which the sum of the diameter of both limbs is < 20 mm.

An adjunctive measure that could overcome the challenge of a narrow distal aorta that is < 20 mm in diameter is the implantation of a balloon-expandable stent in each limb with the kissing-balloon technique (Figure 4). In case of a “napkin-ring” aorta (circumferentially calcified narrow aorta; Figure 4), the use of the so-called paving-and-cracking technique may provide some more room for the deployment of both limbs, but such a maneuver also carries the risk of aortic rupture, which could be a devastating complication, especially in case of endoleaks.¹³

We do not recommend implantation of devices in which the main body artificially elevates the aortic bifurcation with the contralateral gate. In such cases, gate cannulation can be very demanding once the ipsilateral limb is deployed through the narrow distal neck. An alternative endovascular strategy is the use of an aorto-uni-iliac stent graft and a crossover femoro-femoral bypass. We do not recommend this procedure as the first-line treatment in patients with narrow distal aortic necks due to several limitations, such as (1) any limb kinking could lead to a devastating acute aortic occlusion; (2) the procedure requires bilateral groin incisions, which increase the risk of additional morbidity by means of groin or graft infection; and (3) deployment of the contralateral iliac artery occlusion device can be very demanding.

Our Treatment Algorithm for Stenotic Iliac Vessels

The strategy of choice in cases of stenotic iliac vessels is the use of balloon angioplasty in the access vessels prior to aortoiliac endografting and balloon-expandable stenting within the limbs after endografting. According to our experience, use of the paving-and-cracking technique may be required prior to endograft deployment to facilitate endograft advancement. In this scenario, we suggest using the Advanta V12 covered stent in the common iliac artery and the Viabahn stent graft in the external iliac artery. To overcome access issues, ultra-low-profile stent grafts have recently been introduced, but extensive and long-term experience with such devices is still lacking. The use of a balloon-expandable introducer is now available as a recollapsible sheath (SoloPath, Terumo Interventional Systems, Somerset, NJ), and the use of a surgical conduit, mostly an iliofemoral bypass graft, is also recommended.

TORTUOUS ILIAC VESSELS

Although the flexibility of the current endografts has been much improved, tortuous iliac vessels still remain an anatomic challenge, not only during endograft insertion but also when they are used in the DSZ. To the best of our knowledge, the literature lacks comparable data about the impact of tortuosity on EVAR outcomes, due to the subjective grading of iliac artery tortuosity.¹¹ According to EVAR reporting standards, iliac artery tortuosity can be measured with an iliac artery tortuosity index.¹⁹ The index is defined as the ratio between the distance along the central lumen line between the aortic bifurcation and the common femoral artery and the straight line between the same landmarks.²⁰ Despite its accuracy, the use of this index remains complex and time-consuming, and measurement should be performed in different projections.¹¹

In view of the DSZ, severe iliac artery tortuosity may influence limb patency in the long run. Possible mechanisms of limb occlusion in cases of tortuous iliac arteries are limb kinking and suboptimal apposition of the distal end of the limb to the iliac vessel wall. The association between limb kinking and occlusion was previously described. The second mechanism remains a hypothesis of the authors and requires further investigation to be proven. According to our assumption, suboptimal wall apposition of the distal end of the endograft's limb may cause either a high-grade local stenosis or lead to subintimal hyperplasia due to continuous intimal injuries of the iliac vessel (Figure 5).

Our Treatment Algorithm for Tortuous Iliac Arteries

An essential step during EVAR implantation in a tortuous iliac system is the performance of control angiogra-

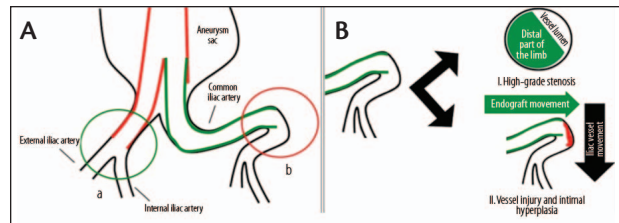


Figure 5. Our assumption about the possible mechanism of limb occlusion post-EVAR due to suboptimal sitting of the distal end of the limb in a tortuous common iliac artery. Optimal position of the right limb (green circle) in a straight right common iliac artery and suboptimal sitting of the left limb (red circle) in the tortuous left common iliac artery (A). Possible mechanisms leading to limb occlusion (I = high-grade stenosis due to reduction of the vessel lumen; II = vessel injury and intimal hyperplasia [red area] associated with the different directions of endograft and artery movement during the cardiac cycle) (B).

phy after removing the extra-stiff wire, with either a soft wire or an angiographic catheter (eg, vertebral or pigtail catheter) kept in place. In our experience, this maneuver will unmask possible graft kinking or suboptimal sitting of the distal end of the endografts, which could not otherwise be identified when the extra-stiff wire is in place.

For graft kinking, our recommended measure is the implantation of an additional bare-metal stent, which will optimize the anatomy of the limb. In cases of suboptimal wall apposition of the distal end of the endograft's limb, we recommend the creation of a composite distal end by supporting the endograft with a self-expanding stent up to a straight part of the common or external iliac artery. Of note, in some cases, overstenting of the internal iliac artery is unavoidable. The substitution of a nitinol stent appears to provide a more gradual transition into the tortuous iliac system.

SUMMARY

A hostile DSZ could include one or more of the following anatomic scenarios: aneurysmatic iliac vessels, a narrow distal aortic neck, and a stenotic or tortuous iliac system. The pathogenic mechanism of DSZ-associated poor outcomes and the influence of a hostile DSZ on the reintervention rates after EVAR are not well investigated. However, limb migration and occlusion are known leading causes for reinterventions after EVAR. There are several endovascular solutions to overcome those challenges, but comparative data are missing to draw robust conclusions. In cases of aneurysmatic DSZ, the use of an iliac side branch device is a well-established method with excellent long-term results and provides an effective solution for aneurysmatic degeneration of the DSZ due

to further progression of the disease. In any case, DSZ has an essential impact on a reintervention-free survival after EVAR and is a factor that should not be overlooked. ■

**The Zenith Branch Iliac Graft is an investigational device in the United States. Limited by United States law to investigational use. It is CE Mark approved with indications for use in the endovascular treatment of patients with an aortoiliac or iliac aneurysm, an insufficient distal sealing site within the common iliac artery, and having morphology suitable for endovascular repair.*

Theodosios Bisdas, MD, is with the Department of Vascular Surgery, St. Franziskus Hospital and University Clinic of Muenster in Muenster, Germany. He stated that he has no financial interests related to this article. Dr. Bisdas may be reached at +49 251 83 45782; th.bisdas@gmail.com.

Giovanni Torsello, MD, is with the Department of Vascular Surgery, St. Franziskus Hospital and University Clinic of Muenster in Muenster, Germany. He stated that he has no financial interests related to this article. Dr. Torsello may be reached at +49 251 83 45782; giovanni.torsello@ukmuenster.de.

1. Dangas G, O' Connor D, Firwana B, et al. Open versus endovascular stent graft repair of abdominal aortic aneurysms: a meta-analysis of randomized trials. *JACC Cardiovasc Interv.* 2012;10:1071-1080.

2. Donas KP, Torsello G, Bisdas T. New EVAR devices: pros and cons. *J Cardiovasc Surg (Tor).* 2012;53:559-569.
3. Schanzer A, Greenberg RK, Hevelone N, et al. Predictors of abdominal aortic aneurysm sac enlargement after endovascular repair. *Circulation.* 2011;123:2848-2855.
4. Norman PE, Powell JT. Site specificity of aneurysmal disease. *Circulation.* 2010;121:560-568.
5. Rayt HS, Bown MJ, Lambert KV, et al. Buttock claudication and erectile dysfunction after internal iliac artery embolization in patients prior to endovascular aortic aneurysm repair. *Cardiovasc Intervent Radiol.* 2008;31:728-734.
6. Torsello G, Schönfeld E, Osada N, et al. Endovascular treatment of common iliac artery aneurysms using the bell-bottom technique: long-term results. *J Endovasc Ther.* 2010;17:504-509.
7. Lobato AC, Camacho-Lobato L. The sandwich technique to treat complex aortoiliac or isolated iliac aneurysms: results of midterm follow-up. *J Vasc Surg.* 2013;57:265-345.
8. Donas KP, Torsello G, Pitoulias GA, et al. Surgical versus endovascular repair by iliac branch device of aneurysms involving the iliac bifurcation. *J Vasc Surg.* 2011;53:1223-1229.
9. Wong S, Greenberg RK, Brown CR, et al. Endovascular repair of aortoiliac aneurysmal disease with the helical iliac bifurcation device and the bifurcated-bifurcated iliac bifurcation device. *J Vasc Surg.* 2013;58:861-869.
10. Austermann M, Bisdas T, Torsello G, et al. Outcomes of a novel technique of endovascular repair of aneurysmal internal iliac arteries using iliac branch devices. *J Vasc Surg.* 2013;58:1186-1191.
11. Donas KP, Bisdas T, Torsello G, Austermann M. Technical considerations and performance of bridging stent-grafts for iliac side branched devices based on a pooled analysis of single-center experience. *J Endovasc Ther.* 2012;19:667-671.
12. Harris PL, Vallabhaneni SR, Desgranges P, et al. Incidence and risk factors of late rupture, conversion, and death after endovascular repair of infrarenal aortic aneurysms: the EUROSTAR experience. European collaborators on stent/graft techniques for aortic aneurysm repair. *J Vasc Surg.* 2000;32:739-749.
13. Nelson PR, Kansal N. The narrow distal aorta. *Endovasc Today.* 2012;10:79-83.
14. Cochenne F, Becquemin JP, Desgranges P, et al. Limb graft occlusion following EVAR: clinical pattern, outcomes and predictive factors of occurrence. *Eur J Vasc Endovasc Surg.* 2007;34:59-65.
15. Bos WT, Tielliu IF, van den Dungen JJ, et al. Results of endovascular abdominal aortic aneurysm repair with selective use of the Gore Excluder. *J Cardiovasc Surg (Torino).* 2009;50:159-164.
16. Van Marrewijk CJ, Leurs LJ, Vallabhaneni SR, et al. Risk-adjusted outcome analysis of endovascular abdominal aortic aneurysm repair in a large population: how do stent-grafts compare? *J Endovasc Ther.* 2005;12:417-429.
17. Cieri E, De Rango P, Isernia G, et al. Effect of stent-graft model on aneurysm shrinkage in 1,450 endovascular aortic repairs. *Eur J Vasc Endovasc Surg.* 2013;46:192-200.
18. Van Zeggeren L, Bastos Goncalves F, van Herwaarden JA, et al. Incidence and treatment results of Endurant endografts occlusion. *J Vasc Surg.* 2013;57:1246-1254.
19. Kristmundsson T, Sonesson B, Resch T. A novel method to estimate iliac tortuosity in evaluating EVAR access. *J Endovasc Ther.* 2012;19:157-164.
20. Chaikof EL, Blankensteijn JD, Harris PL, et al. Reporting standards for endovascular aortic aneurysm repair. *J Vasc Surg.* 2002;35:1048-1060.